

## CASE REPORT

# Non-familial Acrokeratosis Verruciformis of Hopf

Chul Hwan Bang, M.D., Hei Sung Kim, M.D., Young Min Park, M.D., Hyung Ok Kim, M.D., Jun Young Lee, M.D.

Department of Dermatology, The Catholic University of Korea School of Medicine, Seoul, Korea

Acrokeratosis verruciformis of Hopf is a rare genodermatosis with an autosomal dominant mode of inheritance. It is a disorder of keratinization, characterized by multiple, flat-topped, skin-colored keratotic lesions resembling plane warts typically observed on the dorsum of the hands and feet. Histopathologically, the lesion shows considerable hyperkeratosis, acanthosis, and papillomatosis, mimicking a “church spire”, and a thickened granular layer. It arises in early life, often at birth or infancy. Herein, we report on a rare sporadic case of acrokeratosis verruciformis of Hopf. A 44-year-old Caucasian man presented with multiple, grouped, hyperkeratotic, whitish, flat papules on his shins and feet, which had been present for more than one year. Histopathological examination showed typical findings of acrokeratosis verruciformis of Hopf. Our case is unique in that the patient had no familial history of similar skin lesions. (**Ann Dermatol 23(S1) S61~S63, 2011**)

**-Keywords-**

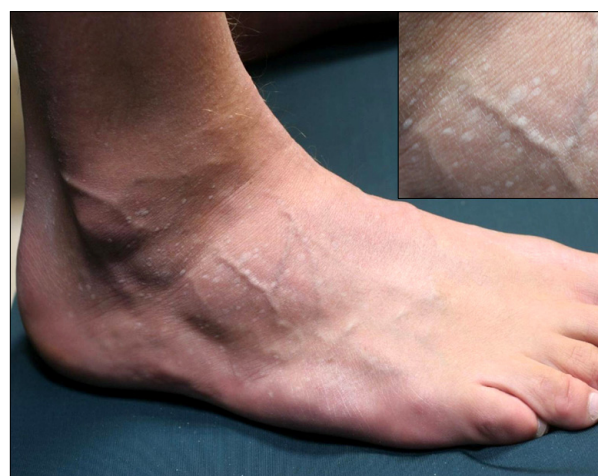Acrokeratosis verruciformis of Hopf, Non-familial acrokeratosis verruciformis

## INTRODUCTION

Acrokeratosis verruciformis (AKV) is a rare hyperkeratotic

genodermatosis, which was first described by Hopf in 1931<sup>1</sup>. It typically presents as multiple, small, flat, wart-like papules on the dorsum of the hands and feet and arises in early life, often at birth or infancy, with no sexual predilection<sup>2,3</sup>. Histologically, it is characterized by hyperkeratosis without parakeratosis, marked papillomatosis without vacuolization, which resembles a “church spire”. Niedelman and McKusick<sup>4</sup> described 24 cases of AKV in 4 generations of a family, and suggested that AKV is inherited in an autosomal fashion. Herndon and Wilson<sup>5</sup> suggested that AKV results from a single dominant genetic defect with variable expressivity. According to Dhitavat et al.<sup>2</sup> AKV is an allelic disorder arising from a missense mutation in ATP2A2. However, a few sporadic cases have also been reported<sup>3</sup>.

We herein report on a rare case of AKV, which developed in a middle-aged person without familial history.



**Fig. 1.** Multiple asymptomatic hyperkeratotic, whitish papules measuring 0.2~0.3 cm on both shins and dorsum of the feet.

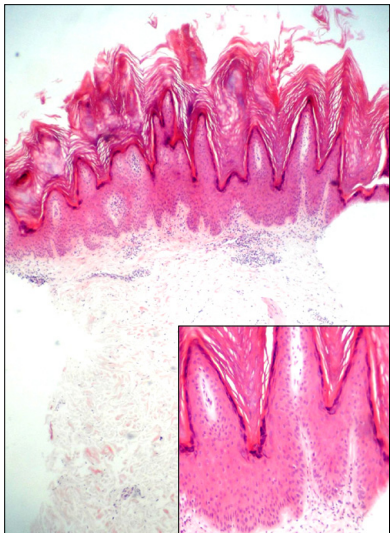
Received September 2, 2010, Revised September 12, 2010, Accepted for publication September 12, 2010

**Corresponding author:** Jun Young Lee, M.D., Department of Dermatology, Seoul St. Mary's Hospital, The Catholic University of Korea School of Medicine, 505 Banpo-dong, Seocho-gu, Seoul 137-701, Korea. Tel: 82-2-2258-1386, Fax: 82-2-594-3255, E-mail: jylee@catholic.ac.kr

This is an Open Access article distributed under the terms of the Creative Commons Attribution Non-Commercial License (<http://creativecommons.org/licenses/by-nc/3.0>) which permits unrestricted non-commercial use, distribution, and reproduction in any medium, provided the original work is properly cited.

CASE REPORT

A 44-year-old Caucasian man presented with multiple asymptomatic papules on both shins and dorsa of feet, which had been present for more than one year. Physical examination revealed numerous whitish papules measuring 0.2~0.3 cm, which appeared to be stuck on the skin, not easily removed by scratching with finger nails (Fig. 1). The wart-like lesions were first detected on the dorsa of the feet and showed a gradual increase in number and size. Similar lesions spread to the anterior aspect of the legs, while the dorsa of hands were spared. No punctate keratoses on the palmoplantar area and no nail involvement were observed. Our patient denied any personal or familial history of skin diseases, like multiple



**Fig. 2.** Hyperkeratosis and hypergranulosis with a “church spire” (H&E, ×40). Magnified view of pure hyperkeratosis, acanthosis, and papillomatosis without parakeratosis, dyskeratosis, and vacuolization (H&E, ×100).

warts, Darier’s disease, or AKV. Biopsy specimens showed marked hyperkeratosis, acanthosis, and papillomatosis, with an increased granular layer. The epidermis looked like a “church spire”, which is a typical finding of AKV. There were no signs of parakeratosis, acantholysis, dyskeratosis, or vacuolization of epidermis (Fig. 2). Based on the clinical and histological findings, we diagnosed our case as a non-familial AKV.

DISCUSSION

AKV is a rare genodermatosis, which develops at birth or during early childhood. However, non-familial cases, like our case, have been reported<sup>3,6-11</sup>. Characteristic findings of AKV include asymptomatic flesh-colored or reddish brown flat papules resembling flat warts. Typically, it arises on the dorsa of the hands and feet, and may extend to the forearms and lower legs. Punctate keratoses of the palms and soles have often been detected in AKV. Clinically, they can be confused with flat warts, epidermodysplasia verruciformis, and especially with Darier’s disease<sup>5,9-12</sup>.

Histopathologically, AKV shows exaggeration of the epidermal layer and thickening of the granular layer. These layers show a blunt, domed pattern within concavities of the wavy stratum corneum, a so called “church spire”<sup>5</sup>. There can be some degree of acantholysis, but not parakeratosis, dyskeratosis, or basal layer change<sup>12</sup>. Clinically mimicking diseases can be ruled out with histopathologic finding. The hypertrophic variant of seborrheic keratosis might present an identical histological finding<sup>6</sup>; however, clinical findings of seborrheic keratosis are far from those of AKV.

As a result of similar clinical and histologic findings, some authors have suggested a possible relationship between AKV and Darier’s disease<sup>9</sup>. However, histopathologically,

**Table 1.** Sporadic cases of acrokeratosis verruciformis of Hopf

Case	Author	Onset age	Site	Palmoplantar pitting	Nail involvement
1	Schuller <sup>6</sup>	40	The dorsal feet and anterior aspects of the legs	Scattered punctate keratoses on the palm	Brittle, but not to an unusual degree
2	Berk et al. <sup>7</sup>	11	The dorsal hands, wrists, feet and ankle	Not invovled	Not invovled
3	Farro et al. <sup>8</sup>	56	Extremities	Not invovled	Not invovled
4	Serarslan et al. <sup>9</sup>	14	The dorsal hands and feet	Not invovled	Not invovled
5	Kaliyadan et al. <sup>10</sup>	20	Chiefly over the lower limb with scattered lesions over the forearms	No other significant skin lesions	No other significant skin lesions
6	Wang et al. <sup>11</sup>	45	The dorsal hands and extensor aspects of forearms	Not invovled	Not invovled
7	This case	43	The dorsal feet and anterior aspects of legs	Not invovled	Not invovled

AKV may be distinguishable from Darier's disease. The unique finding of AKV is a "church spire"; otherwise, that of Darier's disease is benign dyskeratosis with corps round<sup>11,12</sup>.

In terms of the clinical features and histopathological findings, we noticed no difference between familial AKV and non-familial cases. Clinically, both show asymptomatic flesh-colored to reddish brown flat papules resembling flat warts on the dorsa of the feet. In addition, there is a histologically unique finding of a "church spire"<sup>5,12</sup>. In our case, the late onset age and absence of a familial history was confusing; however, with the typical clinical and histopathological findings, we were able to diagnose our patient as non-familial AKV.

We found 6 previously reported cases of sporadic AKV in English literature (Table 1). Like our case, all of these cases showed typical clinical and histopathological findings and lacked a familial history. By review of cases of non-familial AKV, we noticed some differences between familial AKV and non-familial AKV.

The onset age of classical AKV is different from that of sporadic AKV. Classical AKV often occurs during childhood<sup>2,3</sup>, where Panja<sup>12</sup> reported the average onset age of AKV as 11-years-old. However, the onset age of sporadic AKV is much later than that of classical AKV. Four of the seven cases, including our case, developed in patients over 40-years of age, and the average onset age of the seven cases was 32-years-old (Table 1). In addition, palmar and plantar keratoses have frequently been reported in classical AKV<sup>5,12</sup>, but not in sporadic AKV. Only one of seven cases of sporadic AKV showed punctate pits on the palms. However, there is insufficient data for determination of differences of prognosis and recurrence rate between classical AKV and sporadic AKV. Some authors have reported on ATP2A2 gene mutations in AKV<sup>2,7</sup>. Dhitavat et al.<sup>2</sup> reported a novel P602L mutation within the ATP-binding domain of ATP2A2 in classical AKV. On the other hand, Berk et al.<sup>7</sup> reported a A698V codon change in ATP2A2 in sporadic AKV. In addition, A698V codon change has never been described in patients with either classical AKV or Darier's disease<sup>7</sup>. These results suggest that the mechanism and gene

mutation in sporadic AKV may differ from that of classical AKV. In the future, more cases should be studied and genetic studies of sporadic AKV should be conducted.

## REFERENCES

1. Hopf G. Über eine bisher nicht beschriebene disseminierte. Keratose (Akrokeratosis verruciformis). *Dermatologische Zeitschrift* 1931;60:227-250.
2. Dhitavat J, Macfarlane S, Dode L, Leslie N, Sakuntabhai A, MacSween R, et al. Acrokeratosis verruciformis of Hopf is caused by mutation in ATP2A2: evidence that it is allelic to Darier's disease. *J Invest Dermatol* 2003;120:229-232.
3. Alain H. Acantholytic disorders of the skin: Darier-White disease, acrokeratosis verruciformis, Grover disease, and Hailey-hailey disease. In: Wolff K, Goldsmith LA, Katz SI, Glichrest BA, Paller AS, Leffell DJ, editors. *Fitzpatrick's dermatology in general medicine*. 7th ed. New York: McGraw-Hill, 2006:437.
4. Niedleman ML, McKusick VA. Acrokeratosis verruciformis (Hopf). A follow-up study. *Arch Dermatol* 1962;86:779-782.
5. Herndon JH, Wilson JD. Acrokeratosis verruciformis (Hopf) and Darier's disease. Genetic evidence for a unitary origin. *Arch Dermatol* 1966;93:305-310.
6. Schueller WA. Acrokeratosis verruciformis of Hopf. *Arch Dermatol* 1972;106:81-83.
7. Berk DR, Taube JM, Bruckner AL, Lane AT. A sporadic patient with acrokeratosis verruciformis of Hopf and a novel ATP2A2 mutation. *Br J Dermatol* 2010;163:653-654.
8. Farro P, Zalaudek I, Ferrara G, Fulgione E, Cicale L, Petrillo G, et al. Unusual association between acrokeratosis verruciformis of Hopf and multiple keratoacanthomas. Successful therapy with acitretin. *J Dtsch Dermatol Ges* 2004;2:440-442.
9. Serarslan G, Balci DD, Homan S. Acitretin treatment in acrokeratosis verruciformis of Hopf. *J Dermatolog Treat* 2007;18:123-125.
10. Kaliyadan F, Manoj J, Venkitakrishnan S. Acrokeratosis verruciformis of hopf associated with dilated cardiomyopathy. *Indian J Dermatol* 2009;54:296-297.
11. Wang PG, Gao M, Lin GS, Yang S, Lin D, Liang YH, et al. Genetic heterogeneity in acrokeratosis verruciformis of Hopf. *Clin Exp Dermatol* 2006;31:558-563.
12. Panja RK. Acrokeratosis verruciformis: (Hopf)-A clinical entity? *Br J Dermatol* 1977;96:643-652.