

CASE REPORT

Black Hairy Tongue Associated with Erlotinib Treatment in a Patient with Advanced Lung Cancer

Jin Seob Jeong, M.D., Ji Yeoun Lee, M.D., Mi Kyeong Kim, M.D.¹, Tae Young Yoon, M.D.

Departments of Dermatology and ¹Internal Medicine, School of Medicine and Medical Research Institute, Chungbuk National University, Cheongju, Korea

Erlotinib is a tyrosine kinase inhibitor that acts on the epidermal growth factor receptor (EGFR). There have been many reports of the mucocutaneous side effects related to several EGFR inhibitors (EGFRIs). However, no case of black hairy tongue (BHT) associated with EGFRi has been reported. Herein, we report the first case of erlotinib-induced BHT in a 61-year-old man with advanced lung cancer. Considering recent use of EGFRIs worldwide, dermatologists should recognize the possible occurrence of BHT associated with EGFRIs such as erlotinib. (*Ann Dermatol* 23(4) 526~528, 2011)

-Keywords-

Black hairy tongue, Epidermal growth factor receptor inhibitor, Erlotinib

INTRODUCTION

Erlotinib is a tyrosine kinase inhibitor that acts on the epidermal growth factor receptor (EGFR) and has been approved to treat advanced non-small cell lung cancer and pancreatic cancer¹. There have been many reports of the cutaneous or mucosal side effects related to several

EGFR inhibitors (EGFRIs)². However, no case of black hairy tongue (BHT) associated with a EGFRi has been reported. Herein, we report the first case of erlotinib-induced BHT in an elderly man with advanced lung cancer.

CASE REPORT

A 61-year-old man presented with an asymptomatic black discoloration of the tongue that he noticed 1 month earlier. He was diagnosed with advanced lung cancer (squamous cell carcinoma, T4N2M1) 4 months before and had received three cycles of chemotherapy once per month. Due to a lack of efficacy, he began to take erlotinib 100 mg daily 4 weeks after the last chemotherapy. Four days later, he noticed black discoloration and hairy changes on his tongue. A physical examination of the lesion revealed a black discoloration with hairy elevation of the filiform papillae on the dorsal surface of

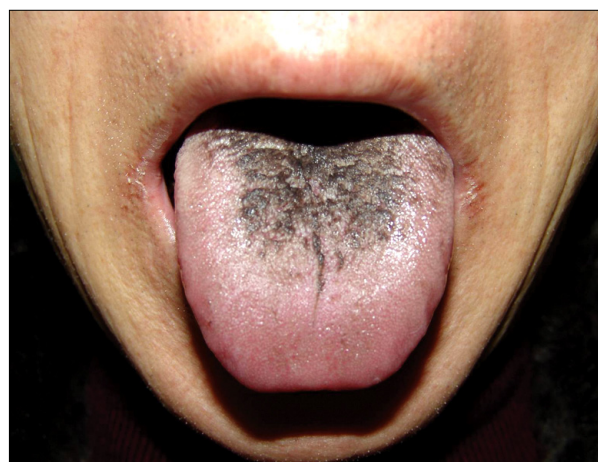


Fig. 1. A black discoloration with a hairy appearance on the dorsal surface of the tongue.

Received August 27, 2010, Revised December 18, 2010, Accepted for publication December 18, 2010

Corresponding author: Tae Young Yoon, M.D., Department of Dermatology, School of Medicine and Medical Research Institute, Chungbuk National University, 52 Naesoodong-ro, Heungdeok-gu, Cheongju 361-763, Korea. Tel: 82-43-269-6369, Fax: 82-43-266-1698, E-mail: tyoon@chungbuk.ac.kr

This is an Open Access article distributed under the terms of the Creative Commons Attribution Non-Commercial License (<http://creativecommons.org/licenses/by-nc/3.0>) which permits unrestricted non-commercial use, distribution, and reproduction in any medium, provided the original work is properly cited.

the tongue (Fig. 1). Otherwise, his physical findings were unremarkable. A KOH examination and fungal culture from the tongue surface were negative. He refused a skin biopsy and further evaluation of his tongue lesion. A diagnosis of BHT was made based on the clinical findings, and erlotinib was subsequently discontinued. However, other medications such as oxycodone, metoclopramide, ranitidine, acetylcysteine, and magnesium oxide were continued to control a variety of complications from lung cancer. His tongue lesion completely resolved 5 weeks after withdrawal of erlotinib.

DISCUSSION

BHT, or lingua villosa nigra, is an unusual, benign, and typically asymptomatic disorder characterized by abnormal elongation and hypertrophy of the filiform papillae of the tongue³. Overgrowth of the filiform papillae caused by defective desquamation of the epithelium results in a hairy appearance and black to brownish discoloration, commonly on the posterior dorsal surface of the tongue⁴. Although the definite pathogenesis of BHT has remained uncertain, many factors are linked to BHT and one of them is antibiotics such as penicillin, erythromycin, tetracycline, doxycycline, and linezolid. Additionally, other medications, including lansoprazole, olanzapine, and bismuth, can precipitate BHT³.

We concluded that the diagnosis of our patient was drug-induced BHT, and that erlotinib was the probable culprit drug based on the expanded Naranjo adverse drug reaction probability scale proposed by Thompson and Kessler³. The patient's total score was at least 5 points according to the onset of BHT temporally related to erlotinib administration (+2), temporally related resolution of BHT after drug withdrawal (+1), and no alternative causes other than erlotinib (+2). The occurrence of BHT was temporally related to treatment with erlotinib, and the lesion improved after discontinuation. No cases of BHT have been associated with EGFRIs treatment despite their various mucocutaneous adverse events, including acneiform eruption, xerosis, paronychia, trichomegaly, and mucosal aphthae².

Psoriasis is usually induced by tumor necrosis factor (TNF)- α and regressed by TNF- α antagonists^{5,6}. In same manner, BHT may be aggravated by EGF and EGFR. Iwasaki et al.⁷ reported that EGF and EGFR are expressed in the lingual mucosa during the morphogenesis of filiform papillae in rats. They suggested that EGF might influence keratin expression in the lingual epithelium. Furthermore, EGF may regulate proliferation and differentiation of cultured epithelial cells derived from the tongue

of adult mice⁸. BHT results from disturbing epithelial desquamation on the filiform papillae of the tongue⁴, whereas EGFRs promote desquamation of the skin as a side effect². Theoretically, EGFRs may be helpful to alleviate a hairy appearance of BHT. Therefore, BHT associated with erlotinib may be a paradoxical phenomenon similar to the worsening of psoriasis during treatment with TNF- α antagonists⁹. Although we cannot clearly explain how erlotinib induces BHT, we presume that erlotinib may interrupt the inherent role of EGF and EGFR in the lingual epithelium.

In summary, our patient met the requirement for a diagnosis of drug-induced BHT, which was related to erlotinib administration. Because the precise mechanism of EGFR and its inhibitor in the pathogenesis of BHT is unknown, further study is warranted to understand this paradoxical phenomenon. Considering recent use of EGFRIs worldwide, dermatologists should recognize the possible occurrence of BHT associated with EGFRIs such as erlotinib.

REFERENCES

1. Marshall J. Clinical implications of the mechanism of epidermal growth factor receptor inhibitors. *Cancer* 2006; 107:1207-1218.
2. Galimont-Collen AF, Vos LE, Lavrijsen AP, Ouwerkerk J, Gelderblom H. Classification and management of skin, hair, nail and mucosal side-effects of epidermal growth factor receptor (EGFR) inhibitors. *Eur J Cancer* 2007;43:845-851.
3. Thompson DF, Kessler TL. Drug-induced black hairy tongue. *Pharmacotherapy* 2010;30:585-593.
4. Manabe M, Lim HW, Winzer M, Loomis CA. Architectural organization of filiform papillae in normal and black hairy tongue epithelium: dissection of differentiation pathways in a complex human epithelium according to their patterns of keratin expression. *Arch Dermatol* 1999;135:177-181.
5. Ettehadi P, Greaves MW, Wallach D, Aderka D, Camp RD. Elevated tumour necrosis factor-alpha (TNF-alpha) biological activity in psoriatic skin lesions. *Clin Exp Immunol* 1994; 96:146-151.
6. Mössner R, Schön MP, Reich K. Tumor necrosis factor antagonists in the therapy of psoriasis. *Clin Dermatol* 2008;26: 486-502.
7. Iwasaki S, Aoyagi H, Yoshizawa H. Immunohistochemical detection of epidermal growth factor and epidermal growth factor receptor in the lingual mucosa of rats during the morphogenesis of filiform papillae. *Acta Histochem* 2007; 109:37-44.
8. Sakai Y, Nelson KG, Snedeker S, Bossert NL, Walker MP, McLachlan J, et al. Expression of epidermal growth factor in suprabasal cells of stratified squamous epithelia: implications for a role in differentiation. *Cell Growth Differ* 1994;

5:527-535.

9. Lee HH, Song IH, Friedrich M, Gauliard A, Detert J, Röwert J, et al. Cutaneous side-effects in patients with rheumatic

diseases during application of tumour necrosis factor-alpha antagonists. *Br J Dermatol* 2007;156:486-491.